COMPARISON OF SIMULTANEOUS VS CONSECUTIVE APPLICATION OF RADIOFREQUENCY AND TARGETED PRESSURE ENERGY: HISTOLOGY STUDY

HISTOLOGICAL EXAMINATION OF SKIN TISSUE IN PORCINE ANIMAL MODEL AFTER SIMULTANEOUS APPLICATION OF MONOPOLAR RADIOFREQUENCY AND TARGETED PRESSURE ENERGY

Brian M. Kinney M.D.[1], Penka Yonkova M.D.[2]

[1]University of Southern California, Division of Plastic Surgery, Beverly Hills, California
[2]Department of Veterinary Anatomy, Histology and Embryology, Faculty of Veterinary Medicine, Trakia University, Stara Zagora, Bulgaria

Published in Journal of Cosmetic Dermatology. 2019

HIGHLIGHTS

- **Simultaneous application** of Monopolar Radiofrequency and Target Pressure Energy showed **profound improvement** in skin tissue when compared to consecutive treatments.
- Animals treated with simultaneous application showed **59% higher increase in collagen** and **64% higher increase in elastin** when compared to consecutive treatments.
- At 1-month follow-up simultaneous application showed **44% higher increase in thickness of the dermis** opposed to consecutive treatment.

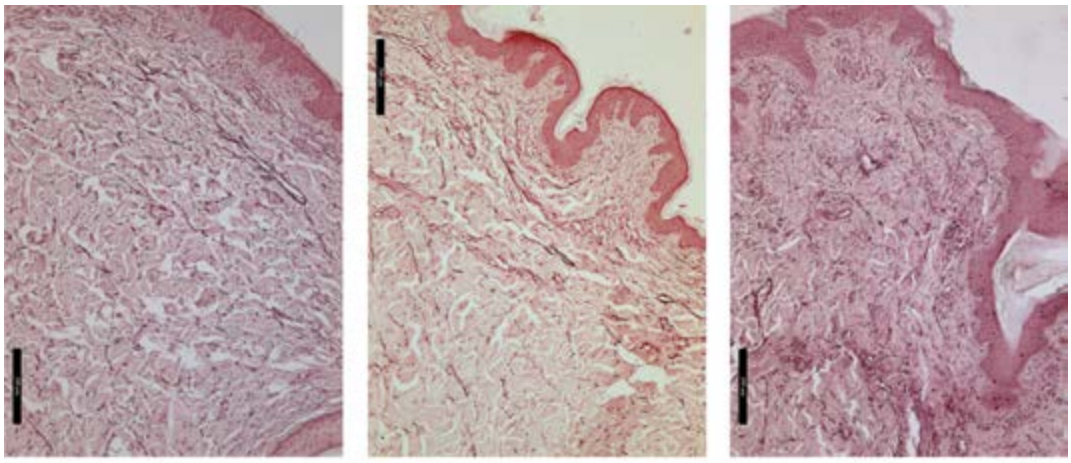

Histological comparison of collagen (pink bundles) and elastin (dark thick strains) densities 1 month after 4th treatment, detail of dermis; Orcein, bar 200 µm.

DESIGN AND METHODOLOGY

- Discover the difference between simultaneous and consecutive application of monopolar RF with Targeted Pressure Energy (TPE).
- All treated pigs received 4 weekly abdominal treatments.
- Animal histology, 5 pigs in total: 2 pigs treated by simultaneous emission of RF and TPE, 2 pigs by consecutive emission, and 1 untreated control pig.
- Skin biopsies were obtained at baseline, after 4th treatment, and at 1-month follow-up.

RESULTS

- This study shows that **simultaneous application** induces a **greater increase of collagen fibers, elastin fibers, and dermal thickness.**
- Combined **TPE and monopolar RF** caused an **increase** in the number of blood vessels in the dermis.
- Application of TPE and monopolar RF affected the **shape and size of adipocytes** (marker of lipolysis).
- The control animal did not show any significant changes.

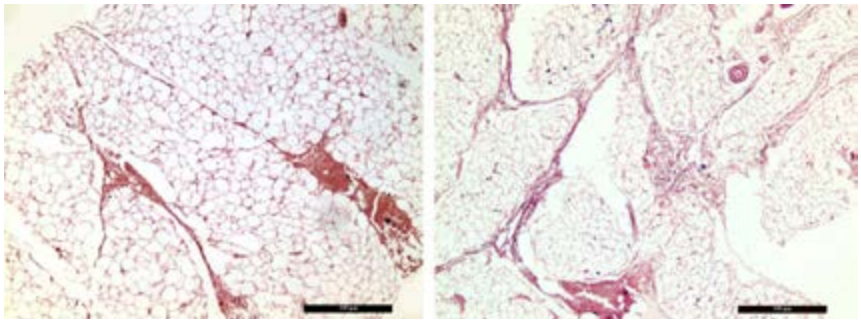

Adipocytes and septa in hypodermis before (left) and 1-month after (right) simultaneous treatment, Orcein, bar 500 µm. Adipocytes are visibly smaller after RF/TPE treatment, while interlobular septa are better organized.

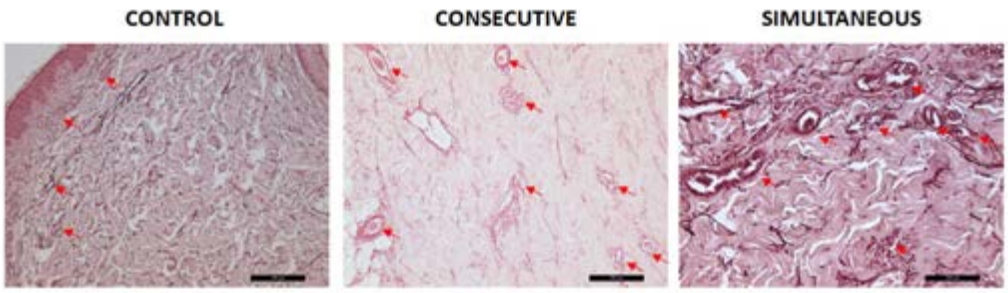

Samples taken at the 1-month follow-up, detail of dermis; Orcein, bar 200 µm; Blood vessels depicted by arrows.