Opinion of a plastic surgeon on lifting treatment with ULTRAcel Q+

Makino Taro
Chief Director of Makino Beauty Clinic

<Outline>
With the introduction of high-intensity focused ultrasound (HIFU), including ULTRAcel Q+, face lifting procedure without invasive surgery or downtime became possible. This has resulted in an increase in the demand for HIFU treatment devices for performing noninvasive face lifting procedures. However, unlike the surgical approach, an operator cannot directly observe the treatment area or touch the target tissue during the treatment using the HIFU device. All HIFU procedures are performed on the surface of the skin. Thus, for accurate and safe treatment using HIFU, it is important that the tissue structure underneath the subcutaneous layer is examined on the basis of aging and to completely understand the features of the device. This paper describes the theories of lifting procedures and provides detailed written commentary regarding the use of ULTRAcel Q+ from a plastic surgeon's perspective, in addition to cases encountered in the clinic.

<Introduction>
Similar to that in the surgical treatment, so as in treatment using HIFU device, understanding the morphological changes in facial tissue from aging over time is important for establishing pre-treatment analysis and strategies in order for safety and securing an effective. This paper begins with the explanation of the anatomical review of "lifting," followed by an explanation of the underlying principle of HIFU, the features of ULTRAcel Q+, and practical techniques as well as protocols.

<Anatomical Review of Face Lifting>
Sagging of the central portion of the face and facial line progresses owing to aging of the overall face. Aging of the overall facial surface refers to the three processes described below:

- Thinning and sagging of the "membrane structure" consists of soft tissues such as skin, superficial musculoaponeurotic system (SMAS), and facial muscles.
- Slackness (sagging) of "supportive tissues," including ligaments that lift the soft tissue.
- Shallow layer of the subcutaneous fat that makes up the facial volume, the characteristics related to area specificity and volume change in the inner layer of subcutaneous fat.

Moreover, other than these three processes, the changes caused by aging in supportive tissue or "skeletal structure," which determines the overall facial volume, should also be considered (Figure 1).

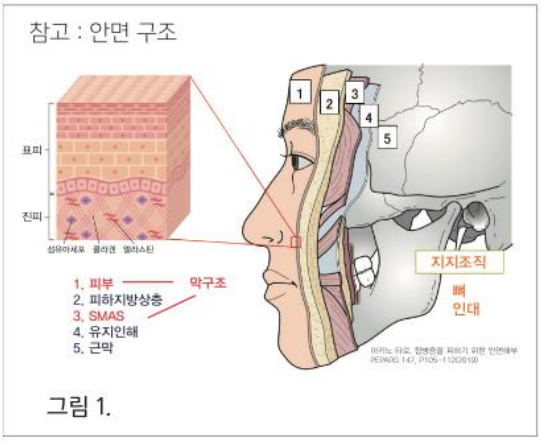

메모 포함[A1]: Translation:
Reference: facial structure

Epidermis,
Dermis
Fibroblast/collagen/Elastin

1.Skin - membrane structure
2.Outer layer of subcutaneous fat
3.SMAS
4. Retaining ligaments
5.Fascia

Supportive structure
Bone
Ligament

Makino Taro, Facial anatomy to avoid complications
PEPARS 147, P106-112 (2019)

Figure.1

Following are the changes observed with the aging of each structure. Changes such as drooping (extension) and slacking (sagging) occur because with an increase in age, the skin tissues lose their elasticity owing to a decrease in their levels of hydration, collagen, elastin, etc. On the other hand, the ligaments are robust tissues and show less sagging; however, because it is attached to the bone tissue, it atrophies with aging and degenerates three-dimensionally; hence, sagging between the ligament and bone tissue begins to occur. Ligaments that are largely related to facial sagging include the zygomatic ligament that is attached to the cheekbone; orbicularis retaining ligament that travels from the periosteum of the orbital rim to the cheekbone; upper and lower masseteric ligaments that radiate to the overall masseter muscle; and the mandibular cutaneous ligament. The bone tissue degenerates with aging, whereas the origin and end of the ligament do not change over time. Hence, sagging and wrinkles are formed around the hollow space created by atrophy of the bone tissue. Moreover, with the loosening of deep ligaments, the SMAS that connects the overall facial structure starts to become thinner and sags irreversibly.
Next is the fat tissue; according to the anatomical validation of fat tissue aging, the inner fat tissue does not continuously extend but exists as independent compartments. The American cosmetic surgeons Dr. Rod J. Rohrich and Dr. Joel E. Pessa (2007) discovered that the subcutaneous fat is divided into compartments, and they proposed the “Fat compartment theory” and described the aging characteristics of each compartment.

Figure 2 is an image of visualizing increase and decrease of fat compartment by dividing into two layers: the superficial subcutaneous fat layer (left) and deep subcutaneous fat layer (right). The picture shows the compartment in which the fat tissue becomes thicker with aging is highlighted in blue; conversely, the compartment that shows thinning is highlighted in red. The positional relationship with the major ligament tissues that are associated with facial sagging is also shown. Notably, all the compartments in the deep subcutaneous fat layer have shown a decrease in fat content with aging, whereas the compartments in the superficial subcutaneous fat layer have distinguished characteristics based on the increase or decrease in fat with aging. The inferior orbital compartment of the lower eyelid and superficial submental fat of the lower jaw decrease in facial volume with aging, whereas the nasolabial compartment at the external nasolabial sulcus, inferior jowl fat compartment external to the marionette line, superficial chin fat compartment at the lower chin, or labiomandibular fat compartment becomes larger with aging, making the nasolabial sulcus deeper and lowering the center of the facial structure which accentuates facial sagging.

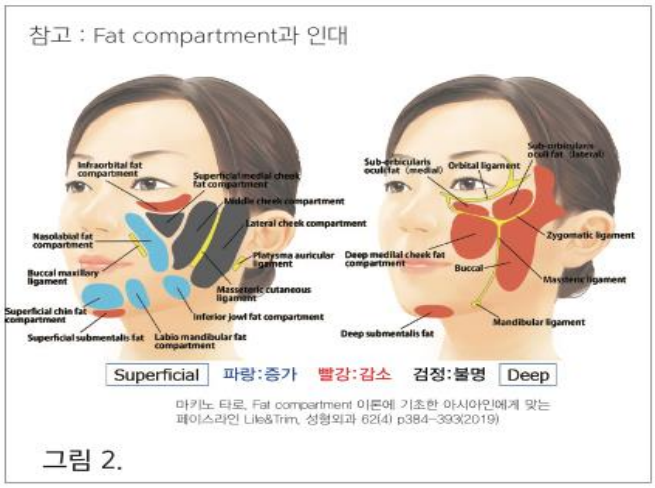

메모 포함[A2]: Image Translation
Reference: Fat Compartment and Ligament

Blue: Increase
Red: Decrease
Black: Unknown

Makino Taro, The facial line that is suitable for Asians based on the Fat compartment theory. Lite & Trim. Plastic surgery. 62(4) p384-393(2019).

Image 2

<Treatment strategy based on anatomical knowledge>

As mentioned earlier, aging causes three-dimensional sagging of the skin, which includes thinning, loosening (drooping), and slacking (sagging) of the "membrane structure," which is composed of the soft tissue, slacking (sagging) of the "supporting tissue," and the increase and decrease in facial volume. Hence, to improve facial sagging caused by aging, treatment of the deeper tissue in addition to the superficial layer is required. SMAS is a membrane tissue that originates from the galea aponeurotica near the head connecting to the temporal muscle and lower platysma and is supported by the deep ligament. It covers various expression muscles and is particularly targeted for lifting treatment strategy. In the field of plastic surgery, various approaches targeting SMAS have been receiving increasing attention because the face-lift procedure that incise SMAS to pull back the skin was found to have a better prolonged effect than the procedure that only makes an incision to the skin to pull up the skin. Moreover, rearranging the distribution of subcutaneous fat, a feature of aging, is important. As part of this step, maintaining the fat compartment that diminish with aging and selectively removing the fat compartment that increases with aging, with respect to the fat compartment theory, are the keys to a successful treatment.

<HIFU enabling operation on SMAS and adipose tissue >

This clinic uses HIFU-based procedures for performing face-lift treatment of patients who "do not wish to undergo excisional surgery of the skin," "hope that there is no downtime," and "have mild sagging skin and do not wish to undergo surgical treatment." HIFU is a procedure leading to middle- to long-term subcutaneous tissue remodeling by stimulating wound healing process and causing contraction of the target tissue through focusing on high-intensity ultrasound to cause heat denaturation. The HIFU device was utilized in lifting treatment mainly because it enables selective heating and denaturing of SMAS in the deep layer, fascia of the muscles of facial expression, and subcutaneous fat tissue in the upper layer that were previously only accessible via a surgical approach. Irradiation of the subcutaneous layer cannot be achieved using other medical devices, including radiofrequency (RF), fractional CO_2 laser, and intense pulsed light, and can only be performed using HIFU (Figure 3).

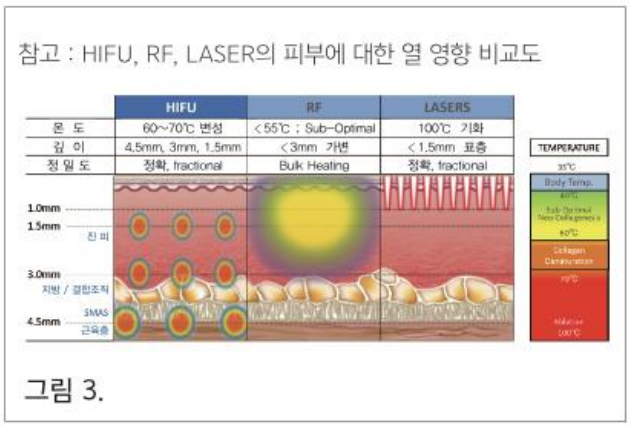

메모 포함[A3]: Translation:
Reference: Comparison of HIFU, RF, LASER for heating effect on skin

Column 1: Temperature, Depth, Precision, dermis, fat/connective tissue, SMAS, muscle layer

Column2: HIFU, 60~70 degrees' Celsius denaturation, 4.5mm,3mm,1.5mm, accurate, fractional

Column3:RF, <55 ; sub-optimal, <3mm variable, Bulk healing

Column4: Lasers, 100 degree's Celsius vaporization, <1.5mm surface layer, accurate, fractional

Figure 3.

This clinic has adopted the most recent version of the HIFU device by Jeisys Medical, ULTRAcel Q+, for performing face-lift procedures. ULTRAcel Q+ is equipped with cartridges of various depths to choose from; by changing the cartridge, the tissue of various layers can be treated: The basement membrane to deeper dermis can be treated with 1.5-mm cartridge, subcutaneous fat layer with 3.0-mm cartridge, and the SMAS layer with 4.5-mm cartridge, enabling safe operation without affecting other tissues.

TREATMENT PROTOCOL

<ULTRAcel Q+ Monotherapy>
This explains a basic lifting treatment protocol using ULTRAcel Q+.
First, the ULTRAcel Q+ application range and choice of cartridge for facial aging has been described in Table 1.

얼굴의 구성요소	조직	노화성 변화	ULTRAcel Q+ 카트리지 선택
막구조	피부	비박화(thinning 얇아짐), 신전(옆으로 늘어짐), 하수(아래로 늘어짐)	1.5mm, 2.0mm
	SMAS	비박화(thinning 얇아짐), 신전(옆으로 늘어짐), 하수(아래로 늘어짐)	4.5mm
지지조직	인대	해이(늘어남)	4.5mm
	골격	흡수되어 위축, 지지 약체화	적응 외
볼륨	골격	위축	적응 외
	지방	비후화(두꺼워짐)	3.0mm, 4.5mm
		비박화(얇아짐)	적응 외

표1. 안면의 노화성 변화에 따른 ULTRAcel Q+의 적응 범위와 카트리지 선택

메모 포함[A4]: Translation:
Row 1: Element of Facial structure /Tissue/changes with aging/ULTRAcel Q+ cartridge
Row 2: Membrane structure/Skin/ thinning, loosening (sideway), sagging (drooping downward) / 1.5mm, 2.0mm
Row 2: Membrane structure/SMAS/ thinning, loosening (sideway), sagging (drooping downward) / 4.5mm
Row 3: Supportive tissue/ligament/loosening/4.5mm
Row 4: Supportive tissue/skeletal structure/atrophy, weakening of support/not applicable
Row 5: volume/skeletal structure/atrophy/not applicable
Row 6: Volume/fat/thickening/3.0mm, 4.5mm
Row 7: Volume/fat/Thinning/not applicable

Table 1. ULTRAcel Q+ application range and choice of cartridge for facial aging

Appropriate cartridges were selected and irradiated by referring to Table 1 and considering the location of the target tissue or nerve to be irradiated when performing the procedure. The sequence of irradiation follows the basic manual of ULTRAcel Q+; however, based on clinical experiences, the effect of the operation was somewhat proportional to the irradiated energy; therefore, higher intensity (1.0–1.2 J in 4.5 mm, 1.0–1.1 J in 3.0 mm, and 0.3 J in 1.5 mm) has been used. To increase the effect and safety of the operation, factors such as paying attention to the dermis structure and selectively irradiating the necessary area as well as being cautious

of the angle during irradiation are important. Figure 4 is a cross-sectional diagram of the area from the facial bones to the dermis and shows that deep ligaments form soft tissue-like anchors. As demonstrated in the image, the area connected to the ligament may easily have a hollow skin surface, and if the ligament atrophies or the fat becomes thinner owing to HIFU irradiation, there is a risk of hollow surface becoming more obvious. Therefore, when using 3.0-mm or 4.5-mm cartridges for the deeper tissue, the area below the temple and cheekbones should be avoided.

Moreover, because having hollow spaces around the border of the fat compartment is easy, 1.5-mm cartridge should be used for irradiating the dermal layer to maintain the fat tissue. The thickness of the subcutaneous fat or skin differs with individual and the area of interest; therefore, the choice of cartridge proposed in Table 1 is just a standard criterion, and in actual use, it is flexibly selected depending on the patients' condition and the treatment area.

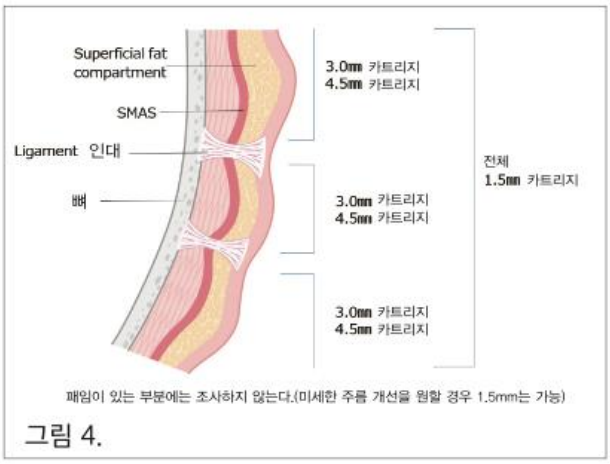

그림 4.

Subjects should be in a supine position during the irradiation, and the cartridge surface is pushed against the skin. Two factors should be considered during this procedure: one is the error in the dermis location due to a change in position caused by lying down (prone position) and sitting down (sitting position) and the other is adjusting the angle appropriately during irradiation considering the feature of ULTRAcel Q+ to concentrate the ultrasound energy.

메모 포함[A5]: Translation:
3.0mm cartridge
4.5 mm cartridge

Superficial fat compartment, SMAS, Ligament, Bone

Total 1.5mm cartridge

Do not irradiate the area with hollow space. (1.5mm is applicable for discrete wrinkle improvement)

Figure 4.

메모 포함[A6]: Translation:
3.0mm cartridge
4.5 mm cartridge

Superficial fat compartment, SMAS, Ligament, Bone

Overall 1.5mm cartridge

Do not irradiate the area with hollow space. (1.5mm is applicable for fine line improvement)

Figure 4.

메모 포함[A7R6]: Translation:
3.0mm cartridge
4.5 mm cartridge

Superficial fat compartment, SMAS, Ligament, Bone

Total 1.5mm cartridge

Do not irradiate the area with hollow space. (1.5mm is applicable for fine line improvement)

Figure 4.

메모 포함[A8]: Translation:
Reference: Energy concentration

<Q4.5>
Coagulation is formed at exact depth and the size of the focal point differs by frequency (Hz). Each cartridge is designed to be appropriate for each indication and area of treatment.

Table row 1: Cartridge/Q4.5/Q3.0
Row 2: Phantom image
Row 3: Depth/Approximately 4.5mm/approximately 3.0mm
Row 4: Energy/4MHz/7MHz
Row5: focal point/wide/narrow

Figure 5.

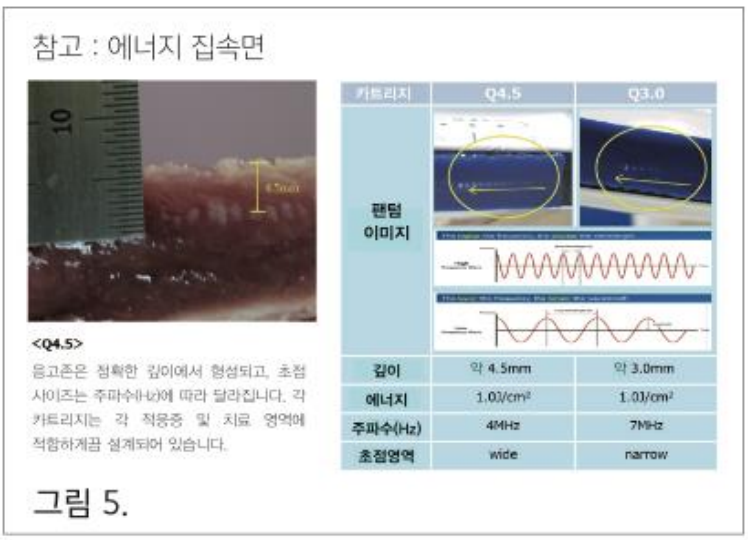

메모 포함[U9]: Response: The translations are as follows:
Note: Energy Interface
Cartridge / Q4.5 / Q3.0
Phantom image/
Depth/about 4.5 mm/ about 3.0 mm
Energy
Hertz/
Focus domain

<Q4.5>
Coagulation zone forms in the exact depth, and the size of focus varies depend on hertz (Hz). The cartridge should be designed appropriately for each indication and treatment area.

Figure 5 is an irradiation test image of using ULTRAcel Q+ in animal tissue sample (image on the left) and phantom, including thermochromic microcapsule (image on the right). Looking at the surface of irradiation from one dimension, the oval-shaped coagulation spots formed by ultrasound irradiation are lined up, which are appearing in a cylindrical shape. Considering these cylinder-shaped coagulation spots as having the functions of stakes connecting each structure, operating in the lying down position allows the energy to move in a vertical direction toward the deep layer, leading to a higher face-lifting effect (Figure 6).

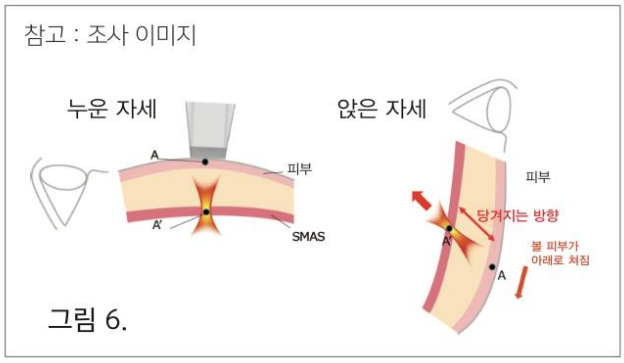

메모 포함[A10]: Translation:
Reference: Irradiation image

Left image: Lying down/Skin
Right image: Sitting Up/Skin/direction of the pull/cheek skin sags downward

Figure 6.

Based on the abovementioned information, a total of approximately 400 shots are irradiated on the entire face and below the jaw (Figure 7). Moreover, when aiming for focused contouring, including facial line, a second pass should be performed directing the cartridge vertically and irradiating in a diagonal direction to increase the pulling effect on the skin.

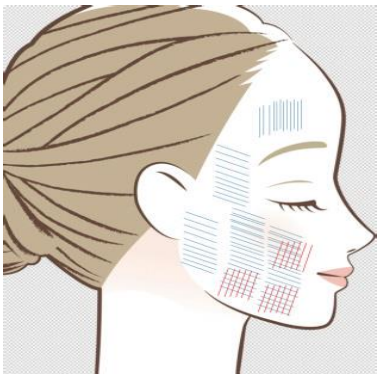

<ULTRAcel Q+> combination therapy>

ULTRAcel Q+ monotherapy is enough to exert a fat-dissolving effect; however, in case faster breakdown of fat is desired, a combination therapy with fat-dissolving injections may be considered. Moreover, in areas in which the volume needs to be maintained, a combination of other injection treatments, including hyaluronic acid injection and fat injection is possible. However, to prevent degeneration of the injected substances owing to the heat produced from the ultrasound of ULTRAcel Q+, the drug injection should be taken after the ULTRAcel Q+ treatment.

CLINICAL CASES

Efficacy of ULTRAcel Q+ is described with the relevant clinical cases.

<ULTRAcel Q+ monotherapy>

- Case 1

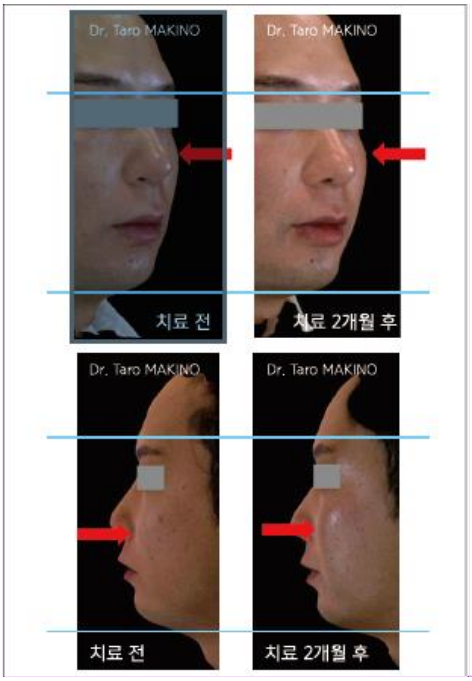

메모 포함[A11]: Translation:
From the first picture: pre-treatment, 2 months post-treatment, pre-treatment, 2 months post-treatment

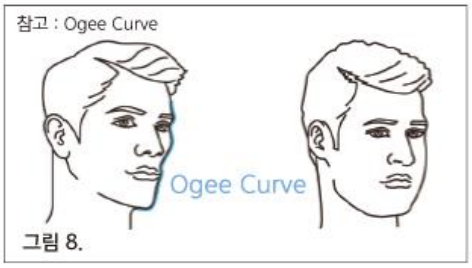

메모 포함[A12]: Translation:
Reference: Ogee Curve
Figure 8.

A 30-year-old male, 2 months post treatment
Comparing the photos taken before treatment and 2 months after the ULTRAcel Q+ treatment, he has an overall healthier and younger impression (CASE 1). Especially, when observing from the side or in a skewed angle, the highest point of the cheek is lifted upward, making the feature of an “Ogee curve” (Figure 8) very obvious, which is an important factor contributing to younger impression.

- Case 2.

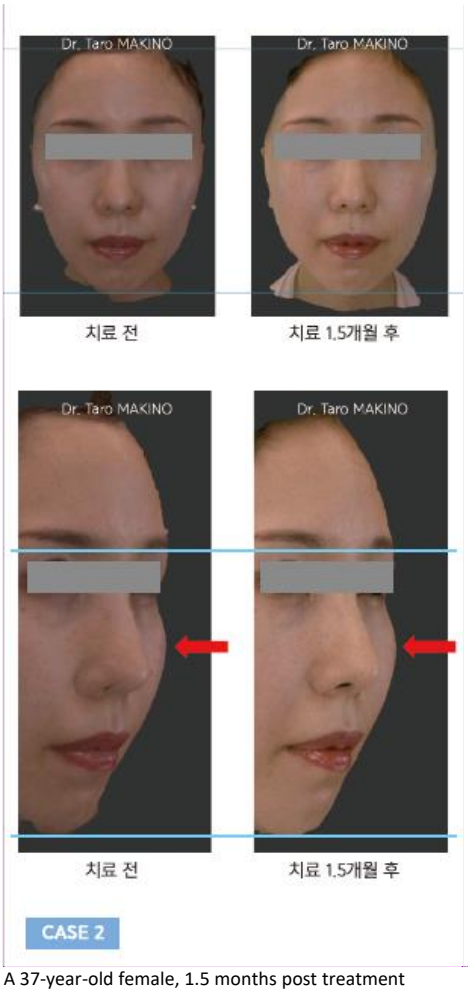

메모 포함[A13]: Translation:
Pre-treatment, 1.5 months post-treatment
Pre-treatment, 1.5 months post-treatment

A 37-year-old female, 1.5 months post treatment
Despite the mild sagging symptoms in the beginning, the position of the cheek near the cheekbone has been lifted up, giving a younger impression.

- Case 3

메모 포함[A14]: Translation:
Pre-treatment, 2 months post-treatment
Pre-treatment, 2 months post-treatment
Pre-treatment, 2 months post-treatment

A 53-year-old female, 2 months post treatment
With the upward lifting of the cheek and lower eyelid, a volume and lifting effect on the cheek is noted.

<Combination therapy of ULTRAcel Q+ and injection treatment>

- Case 4

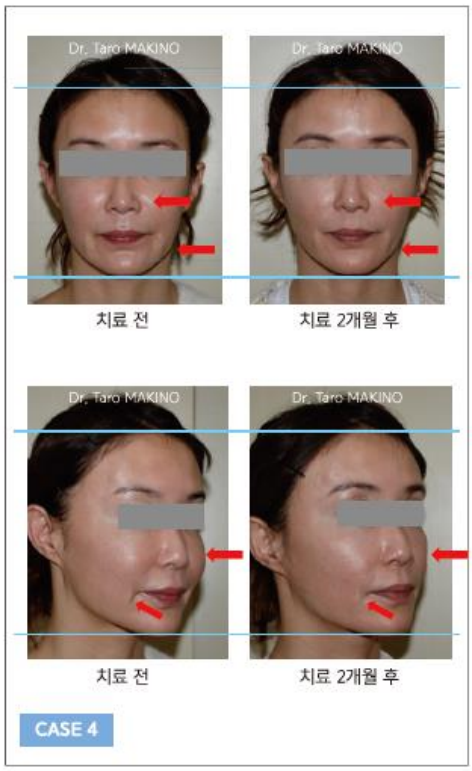

메모 포함[A15]: Translation:
Pre-treatment, 2 months post-treatment
Pre-treatment, 2 months post-treatment

A female in her 30s, 2 months post treatment with ULTRAcel Q+ and deoxycholic acid
After ULTRAcel Q+ operation, deoxycholic acid, a fat-dissolving agent, was injected. The upper part of the nasolabial line became convex, and the loosening cheek was lifted, thereby improving the sagging symptoms.

- Case 5.

메모 포함[A16]: Translation:
Pre-treatment, 6 months post-treatment
Pre-treatment, 6 months post-treatment
Pre-treatment, 6 months post-treatment

A female in her 30s, 6 months post treatment with ULTRAcel Q+, deoxycholic acid, and hyaluronic acid
After ULTRAcel Q+ treatment, fat-dissolving deoxycholic acid and hyaluronic acid were injected. Area below the jaw and the facial line became tensive, whereas the cheek and forehead became more elastic, giving an overall young and lively contour.

<Review and Conclusion>

Because various medical devices are becoming available in the medical aesthetics field, the demand for energy-based treatment with low invasion for face-lift treatment is also rising. The energy-based face-lift treatment device has been continuously changing, starting from laser to IPL, RF, and RF needle. These treatment methods can bring about higher treatment effect, but the heat energy dissipated to the epidermis is unavoidable and there is higher risk of adverse events, including stronger pain, bleeding, swelling, and longer downtime (Figure 9). Especially when high-level IPL and RF are irradiated to yield high effect, a lot of energy is

absorbed through the epidermis, causing burns and inflammation, which can lead to hyperpigmentation and other complications.

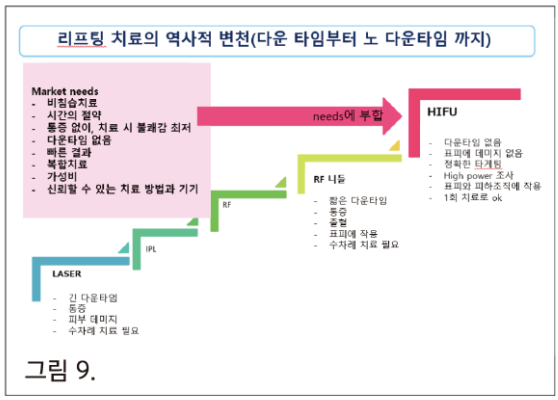

그림 9.

In the midst of such a situation, HIFU using ultrasound technology was introduced, and accessing the SMAS layer, which was possible only during surgical treatment, became available. With the HIFU technology, only the target layer in the subcutaneous layer is irradiated using a transducer; hence, there is no epidermal damage, pain during procedure, or long downtime. HIFU has an outstanding lifting effect and compared with existing treatments, it can be expected to produce more pronounced results; thus, patient satisfaction is high for this treatment.

Particularly, the ULTRAcel Q+ used in this hospital is expected have enough treatment effect, as can be seen in the pictures of the clinical cases, to evaluate the change objectively. The serviceability of the device is excellent, and its ability to change the target depth by simply replacing the cartridge is also one of its favorable characteristics. Moreover, by assessing the clinical cases, ULTRAcel Q+ is considered a device that is associated with low incidence of complications even among other HIFU devices. Another advantage of HIFU is that because it does not have any downtime, treatment options such as combination treatment with injection treatments are expanded, and the resulting synergistic effect can be sought after.

The HIFU devices, which do not remain within the limits of existing energy-based procedures and have numerous possibilities, can be suitable for the current market atmosphere which desires useful and less invasive treatments as an introduction to lifting treatments and also the core of combination treatment.

References

1. Retaining ligaments of the face: review of anatomy and clinical applications Aesthet Surg J. 2013 Aug 1;33(6):769-82.

2. 分冊 解剖学アトラスⅠ第 6 版. W. Platzer　文光堂

3. The fat compartments of the face: anatomy and clinical implications for cosmetic surgery Plast Reconstr Surg. 2007 Jun;119(7):2219-27.

4. Fat compartment 理論に基づいたアジア人に適したフェイスリフト - Lift & Trim -牧野太郎 形成外科 2019;62(4):384-393.

5. Anatomy of the facial fat compartments and their relevance in aesthetic surgery J Dtsch Dermatol Ges. 2019 Apr;17(4):399-413.

6. Lateral SMASectomy, plication and short scar facelifts: indications and techniques Clin Plast Surg. 2008 Oct;35(4):533-50.

메모 포함[A17]: Translation:

Historical evolution of lifting treatment (From downtime to zero downtime)

Market needs
- -Non-invasive treatment
- -Time-saving
- -Painless, minimal discomfort during treatment
- -No downtime
- -Quick results
- -Combination treatment
- -Cost-effective
- -Reliable treatment methods and devices

➔Adhering to the needs

HIFU
- -No downtime
- -No damage to the epidermis
- -Accurate targeting
- -High power irradiation
- -Acts on the epidermis and subcutaneous tissues
- -1 treatment session is enough

RF needle
- -Short downtime
- -Pain
- -Bleeding
- -Acts on the epidermis
- -Multiple treatment sessions required

LASER
- -Long downtime
- -Pain
- -Damage to the skin
- -Multiple treatment sessions required

Figure 9.